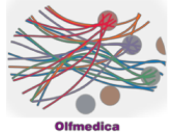


Case 18



Case Details

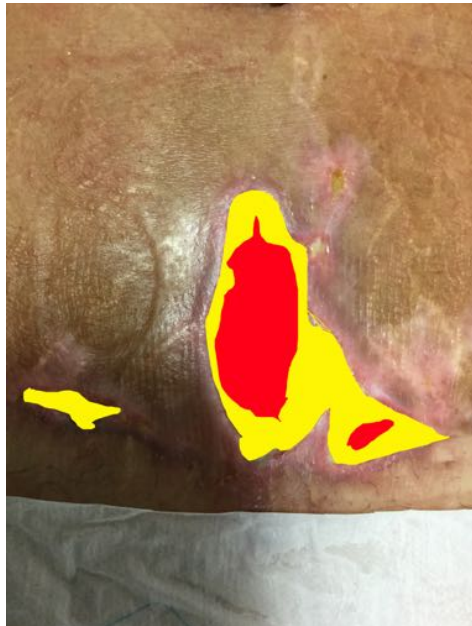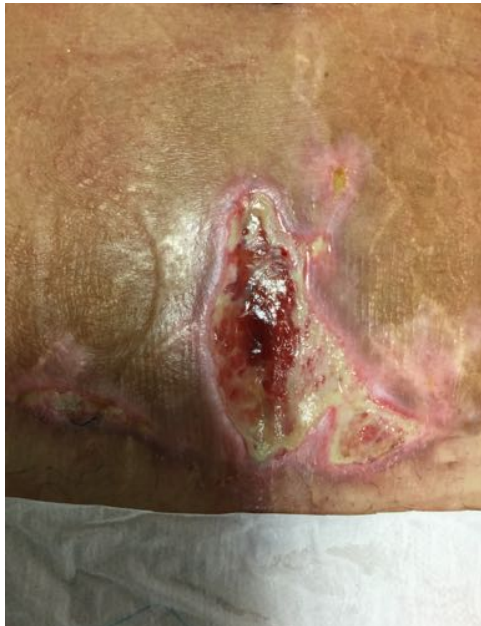Female 56 years

Healthy

Necrosis and ulceration of skin following abdominoplastic surgery developed for 4 weeks

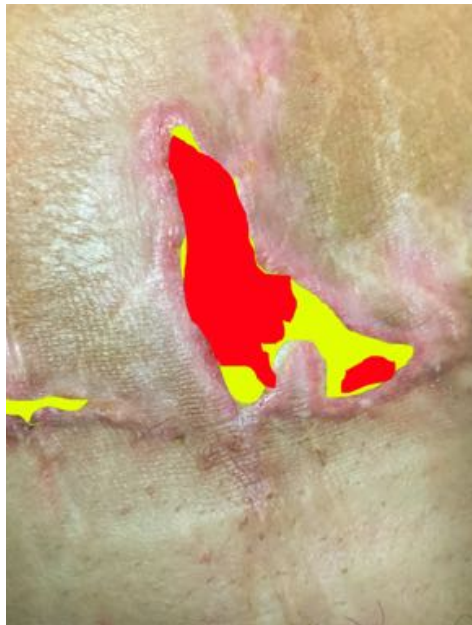
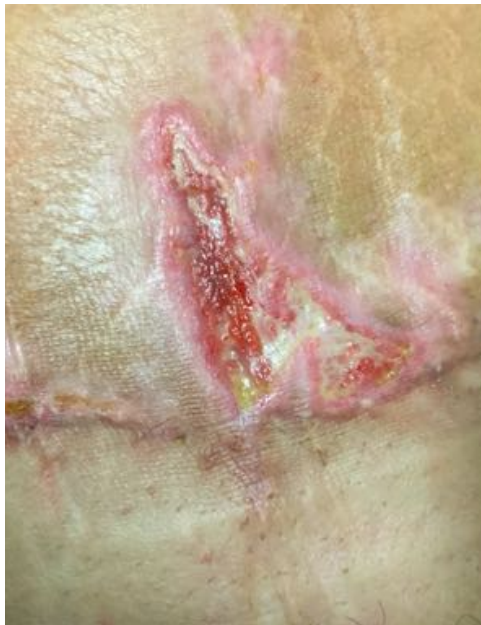Closed in 4 weeks / 12 sessions / no complications

Analysis



20.04.2018

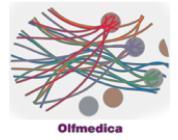
Necrosis:	0%
Fibrin:	60%
Granulation:	40%



27.04.2018

Necrosis:	0%
Fibrin:	32%
Granulation:	68%

Case 18

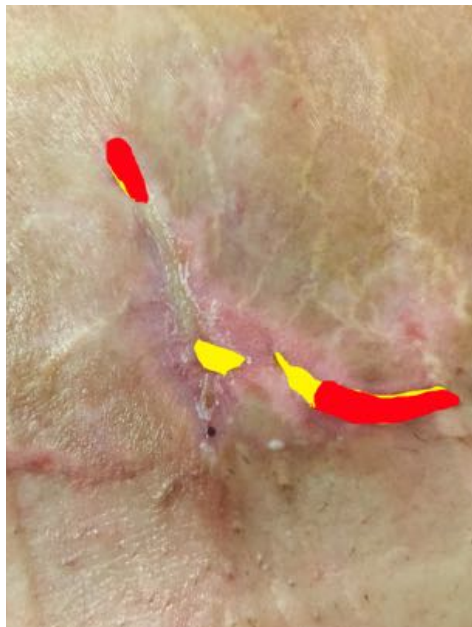
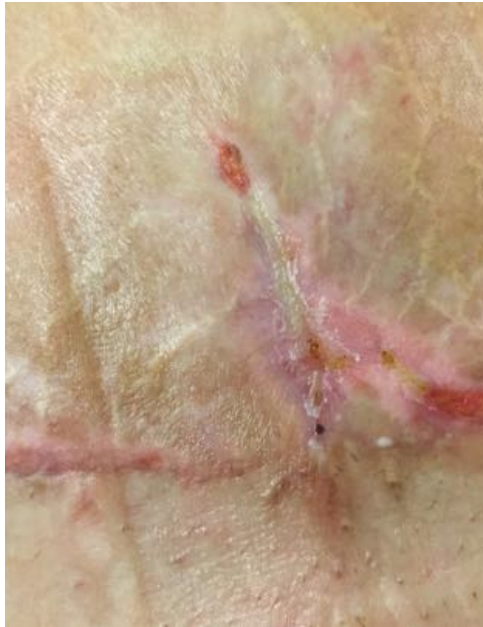
15.05.2018

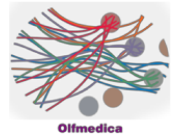
Necrosis: 0%

Fibrin: 30%

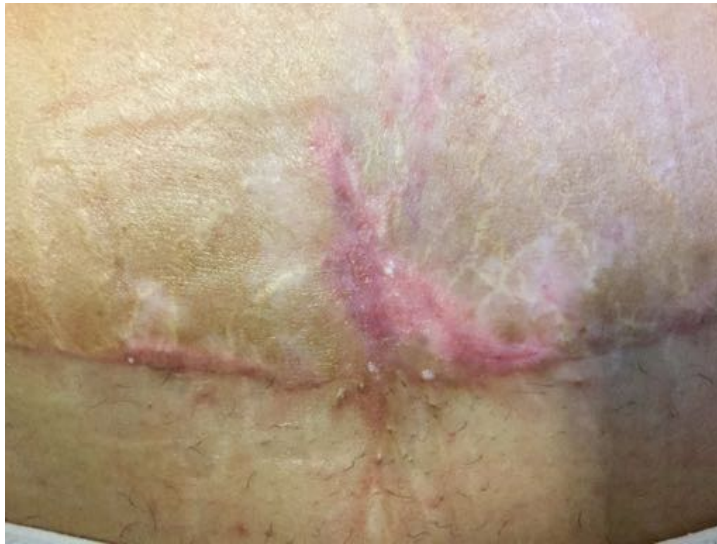Granulation: 70%



Case 18



Result 24.02.2017



Evolution

