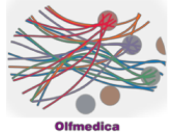


Case 17



Case Details

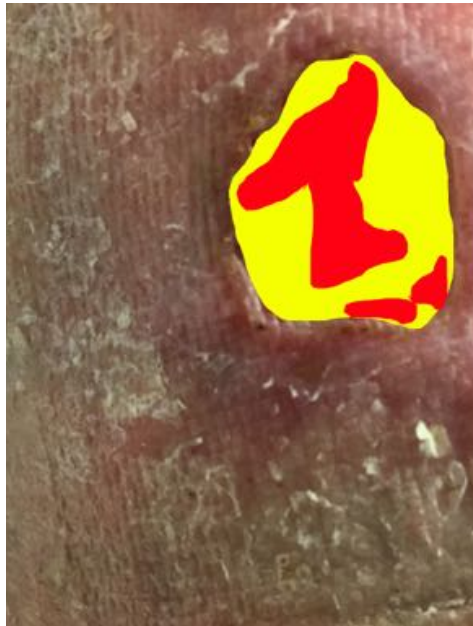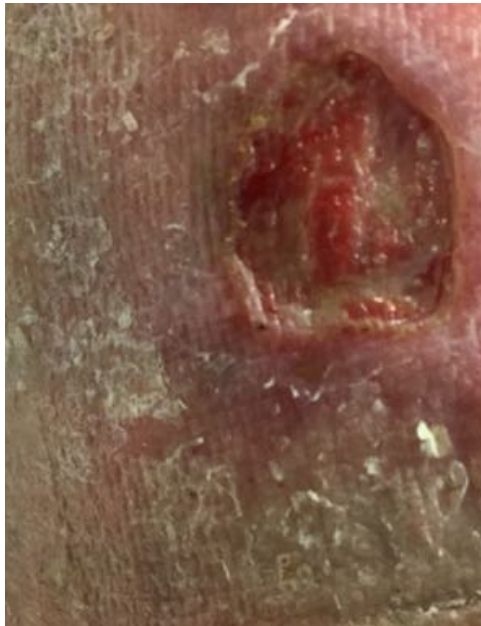Male 76 years

Preconditions: CVI

Recurring venous ulcer developed for 8 weeks

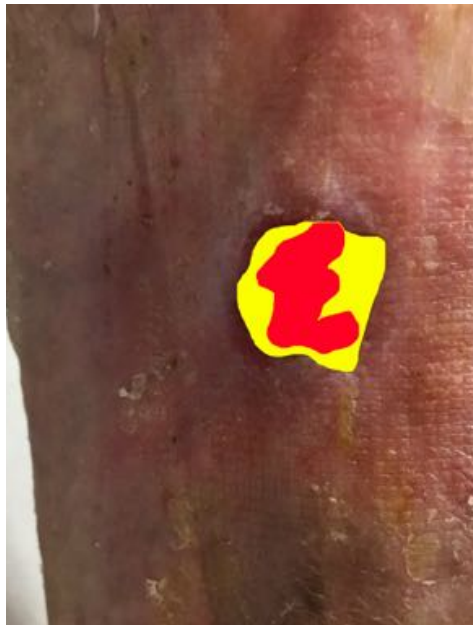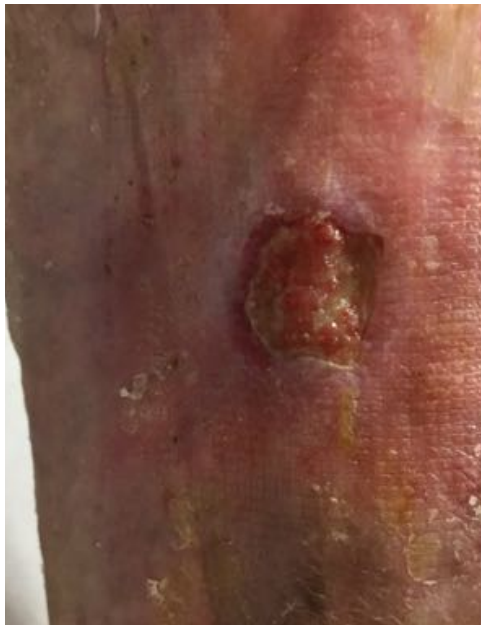Closed in 7 weeks / 21 Sessions / no complications

Analysis



16.04.2018

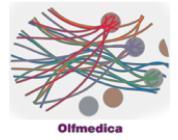
Necrosis:	0%
Fibrin:	59%
Granulation:	41%



30.04.2018

Necrosis:	0%
Fibrin:	48%
Granulation:	52%

Case 17

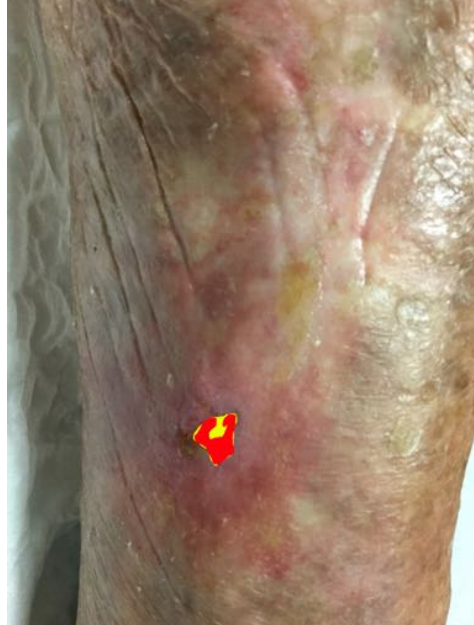
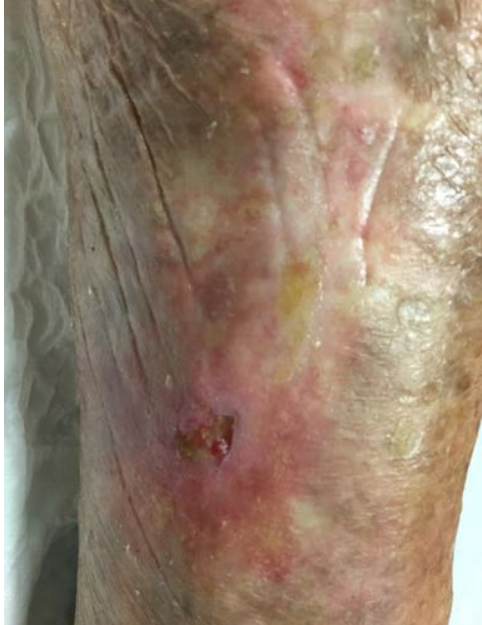
28.05.2018

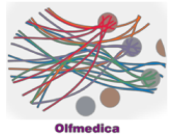
Necrosis: 0%

Fibrin: 21%

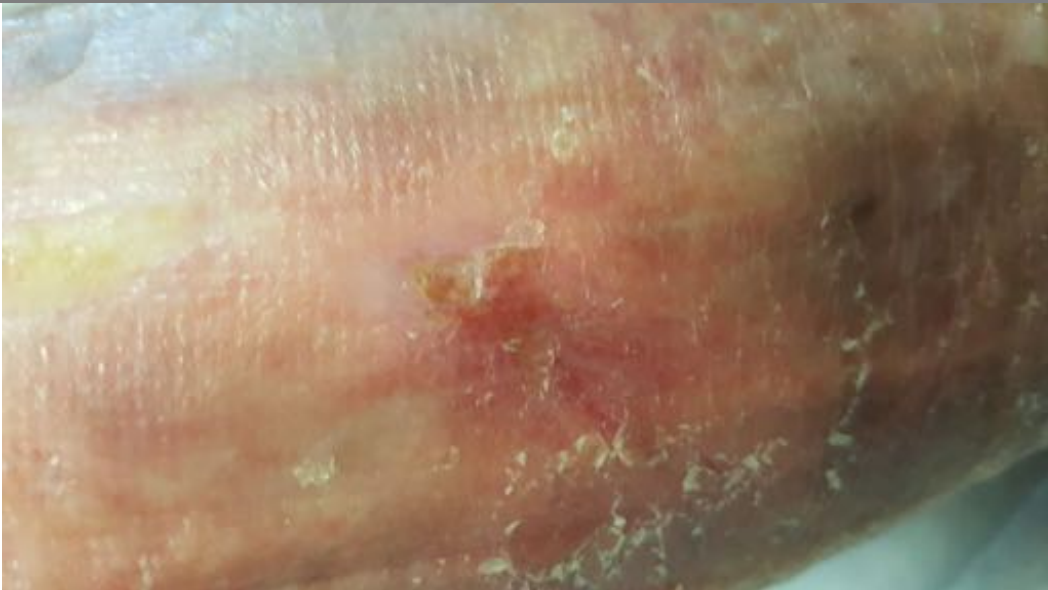Granulation: 79%



Case 17



Result 24.02.2017



Evolution

