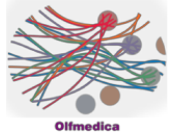


Case 16



Case Details

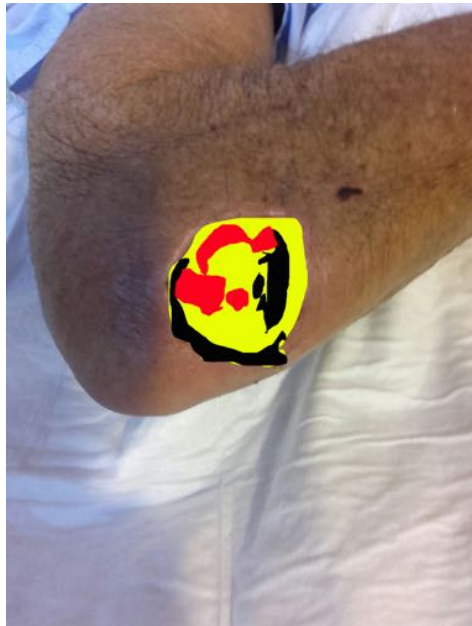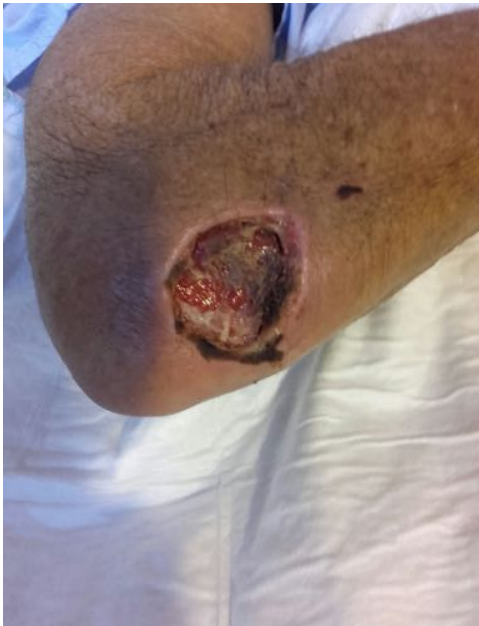Female 79 years

Preconditions: Stroke, atrial fibrillation treated with antiarrhythmics and Anticoagulants

Traumatic ulcer developed for 6 weeks

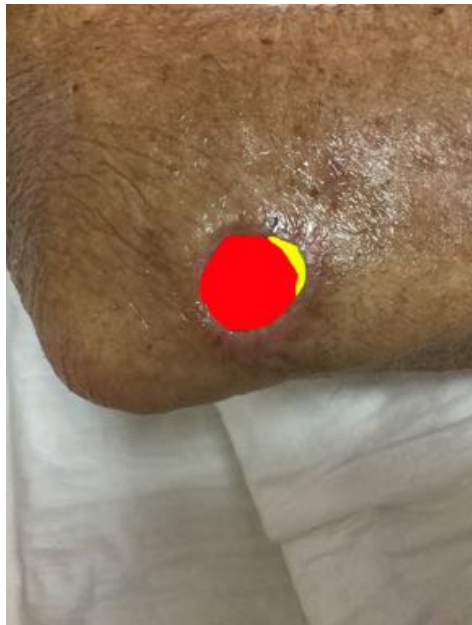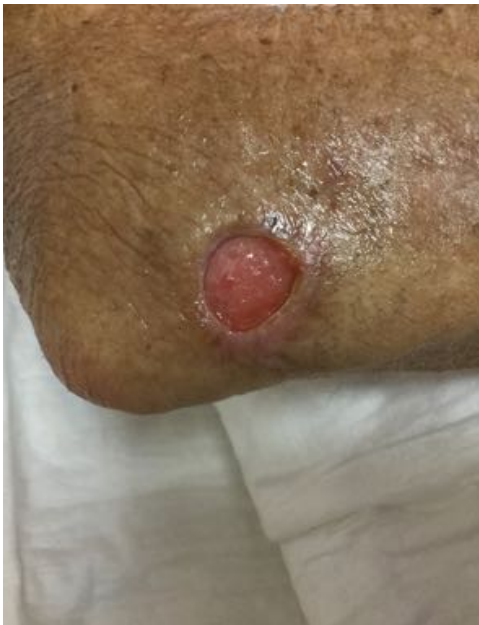Closed in 11 weeks / 33 sessions / No complications

Analysis



06.04.2018

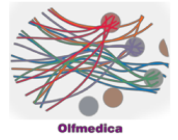
Necrosis:	28%
Fibrin:	51%
Granulation:	21%



13.05.2018

Necrosis:	0%
Fibrin:	8%
Granulation:	92%

Case 16

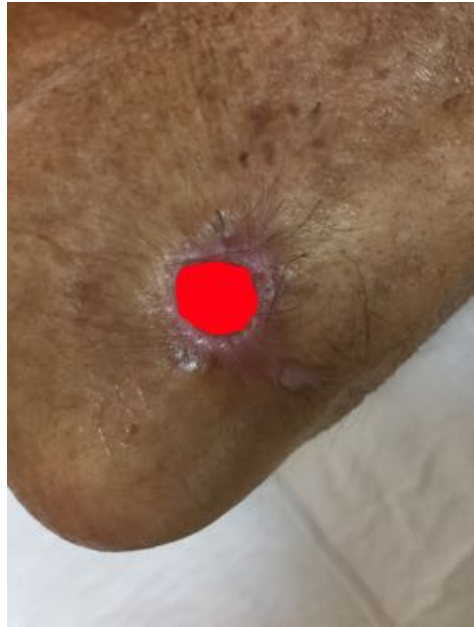
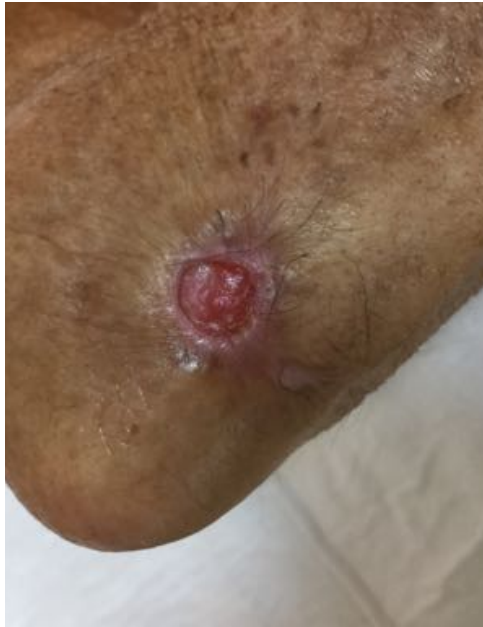
14.06.2018

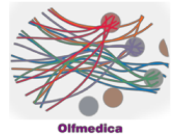
Necrosis: 0%

Fibrin: 0%

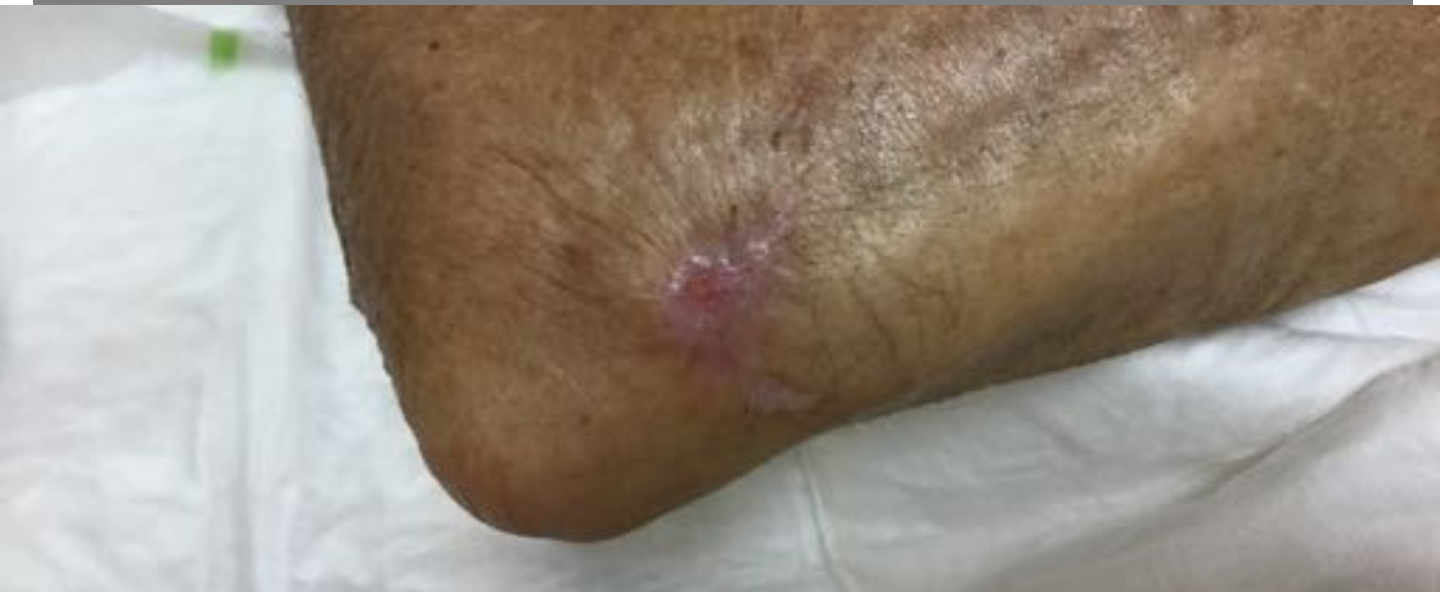Granulation: 100%



Case 16



Result 24.02.2017



Evolution

