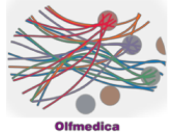


Case 15



Case Details

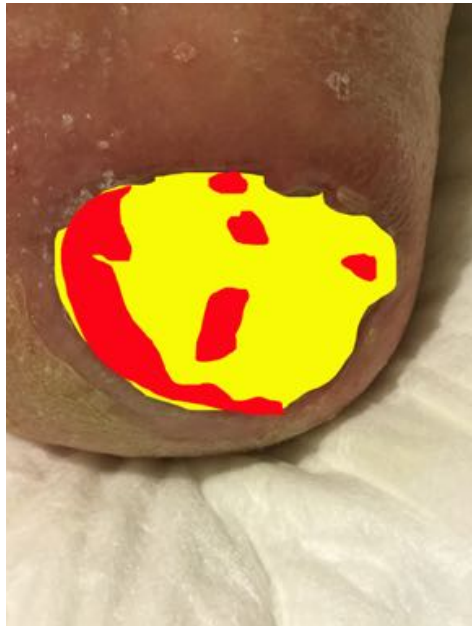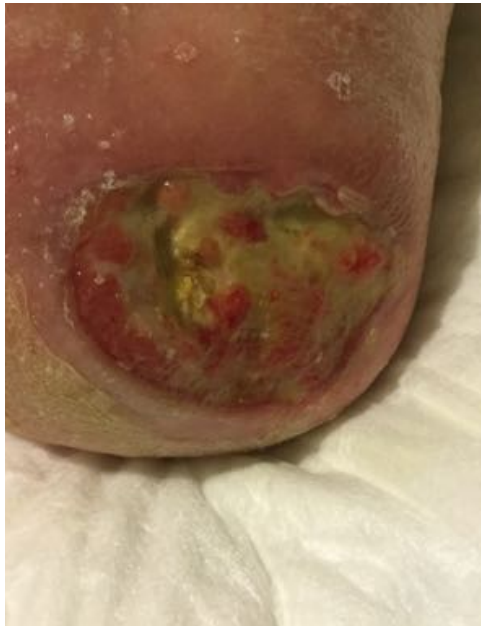Male 87 years

Preconditions: Arterial hypertension and treatment with antihypertensive drugs. CVI. Bowel Cancer with hepatic metastases

Decubitus Ulcer at right heel developed for 10 weeks.

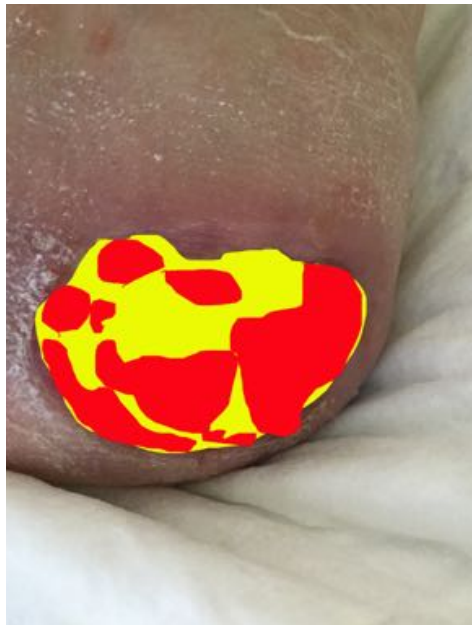
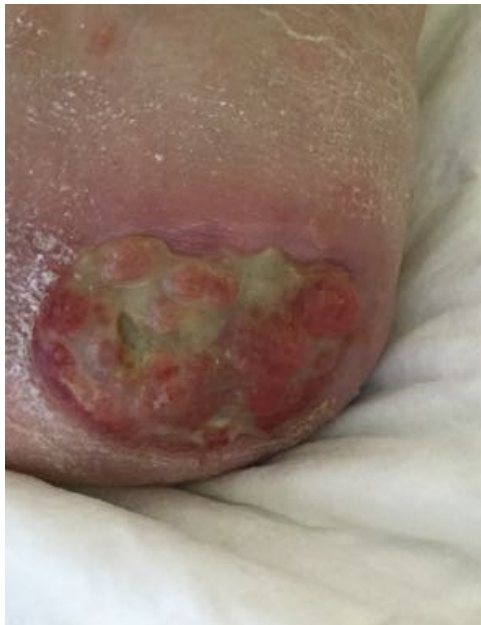Closed in 6 weeks / 18 sessions / no complications

Analysis



29.03.2018

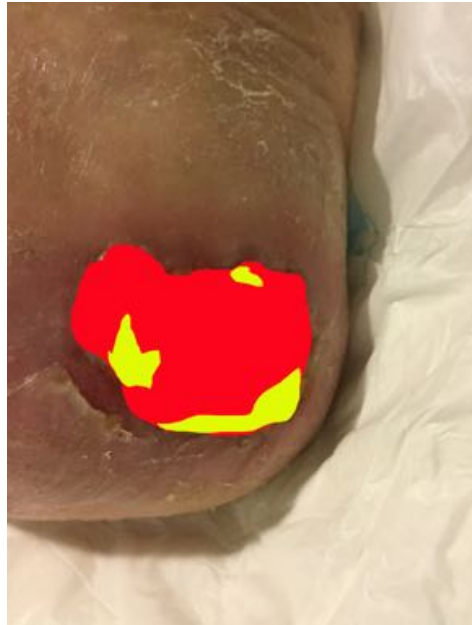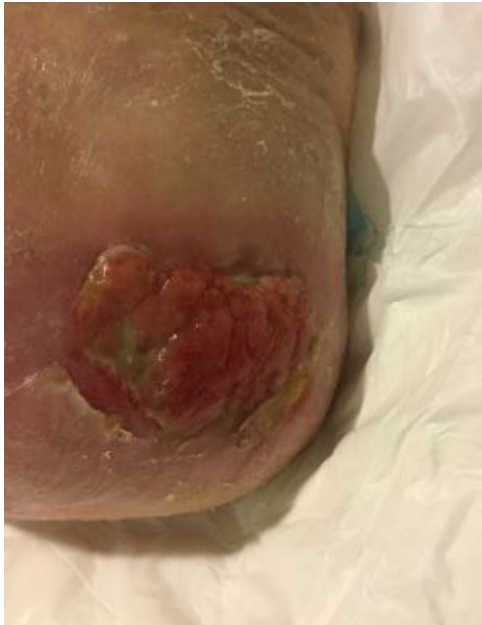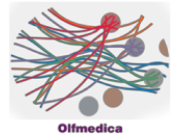
Necrosis:	0%
Fibrin:	71%
Granulation:	29%



11.04.2018

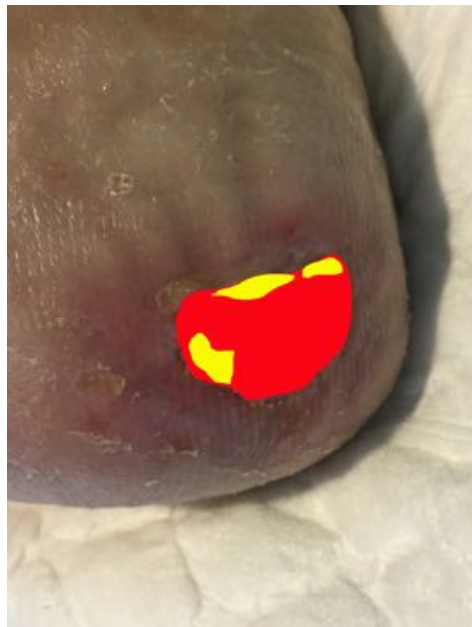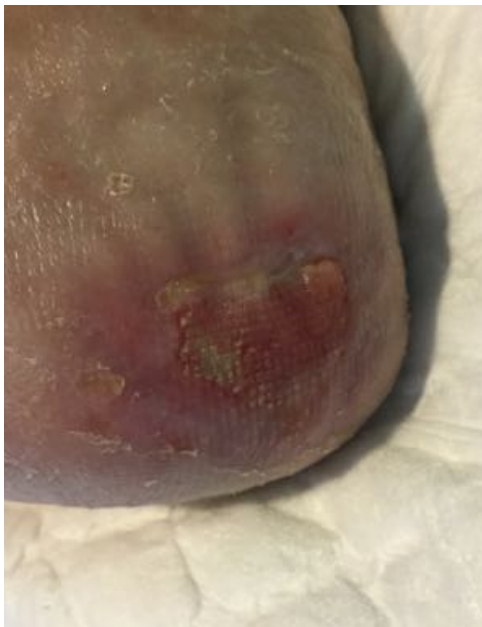Necrosis:	0%
Fibrin:	37%
Granulation:	63%

Case 15



24.04.2018

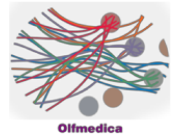
Necrosis:	0%
Fibrin:	16%
Granulation:	84%




03.05.2018

Necrosis:	0%
Fibrin:	17%
Granulation:	83%

Case 15



Result 24.02.2017



Evolution

