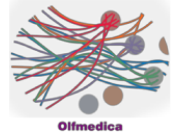


Case 14



Case Details

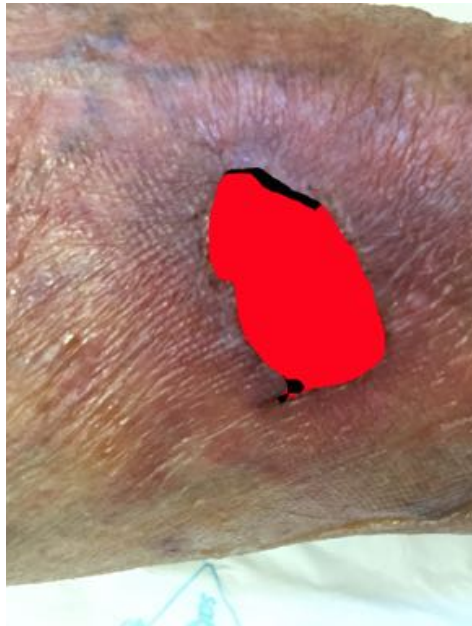
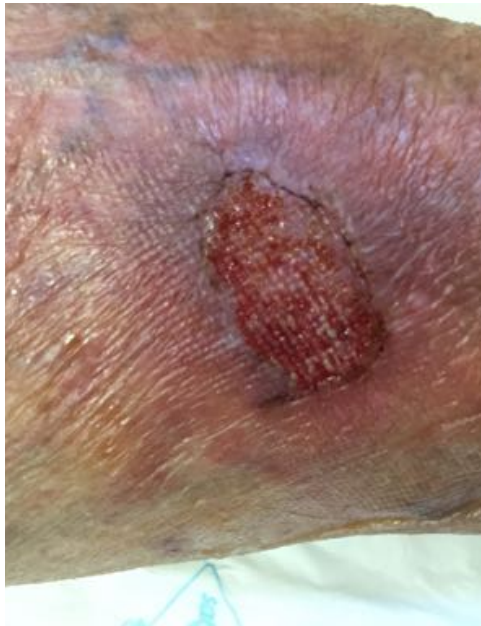
Female 89 years

Preconditions: Chronic bronchitis and treatment with bronchodilators and corticoids. Cutaneous atrophy. Smoker.

Traumatic skin tears developed for 3 weeks

Closed in 2 weeks / 6 sessions / no complications

Analysis

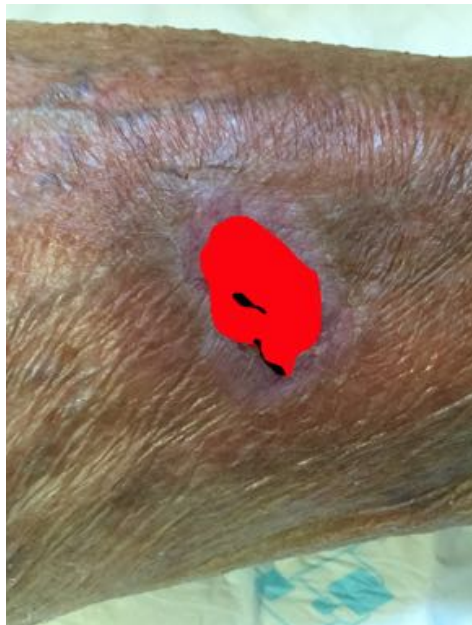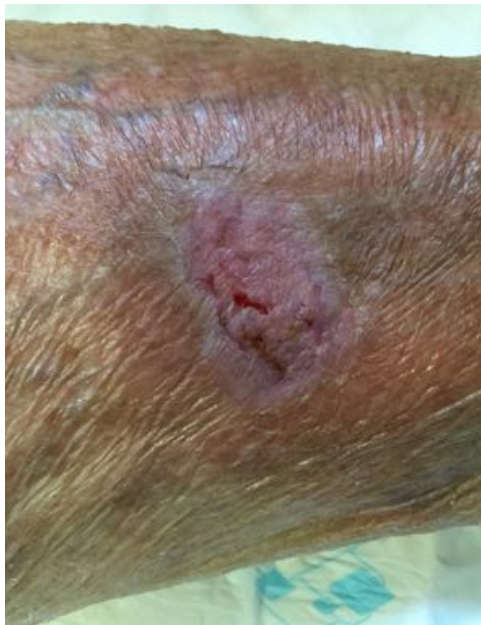


18.10.2018

Necrosis: 4%

Fibrin: 0%

Granulation: 96%



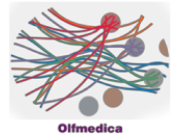
26.10.2018

Necrosis: 3%

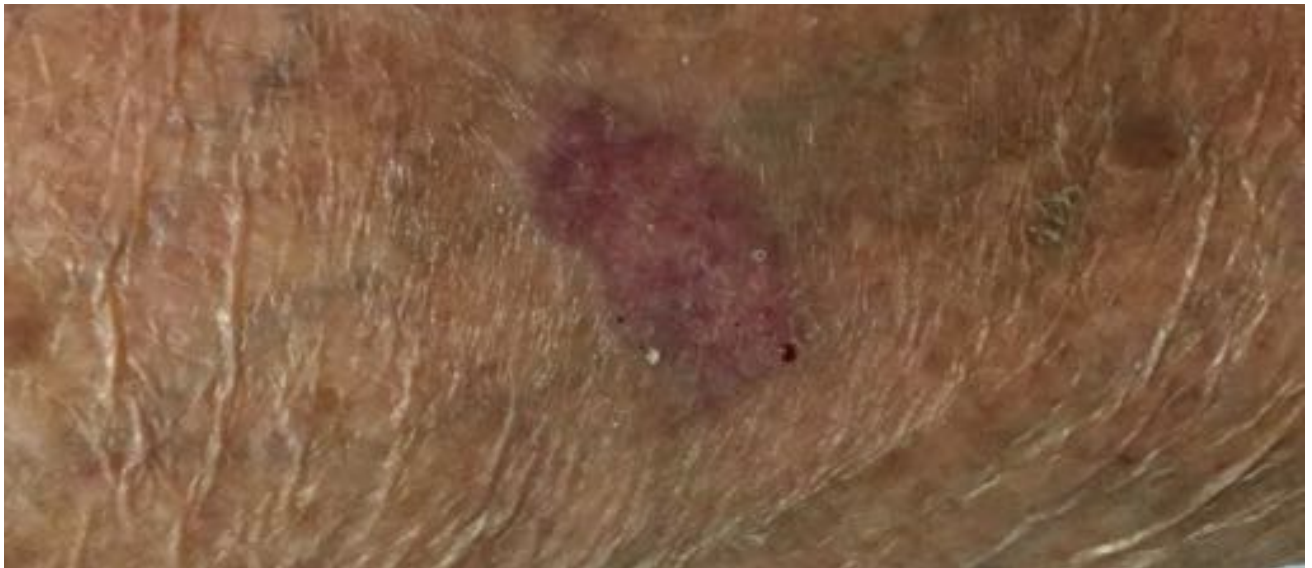Fibrin: 0%

Granulation: 97%

Case 14



Result 24.02.2017



Evolution

