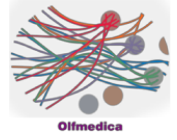


Case 13



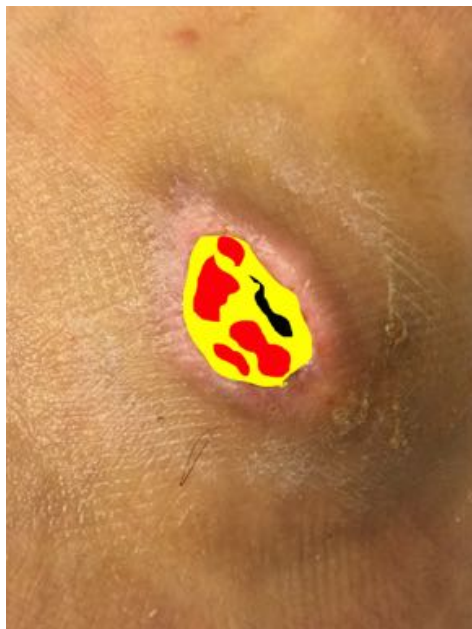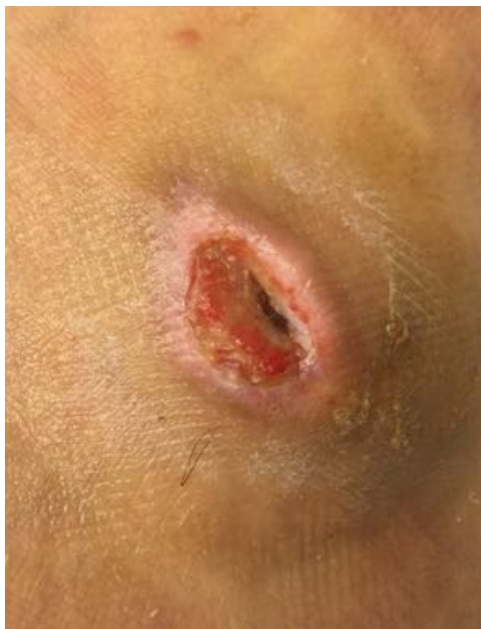Case Details

Male 33 years / Healthy

Traumatic ulcer at left exterior ankle developed for 4 weeks

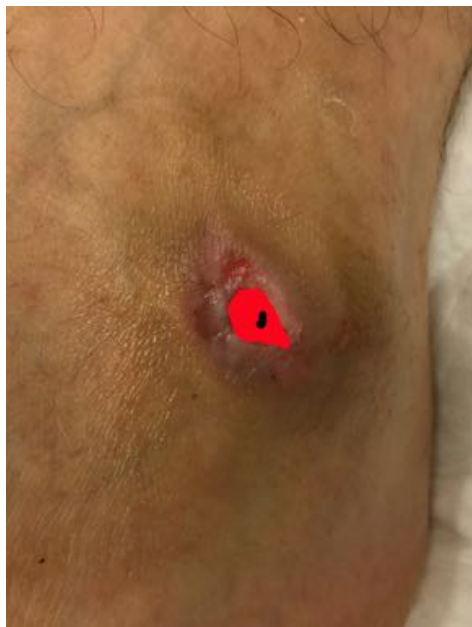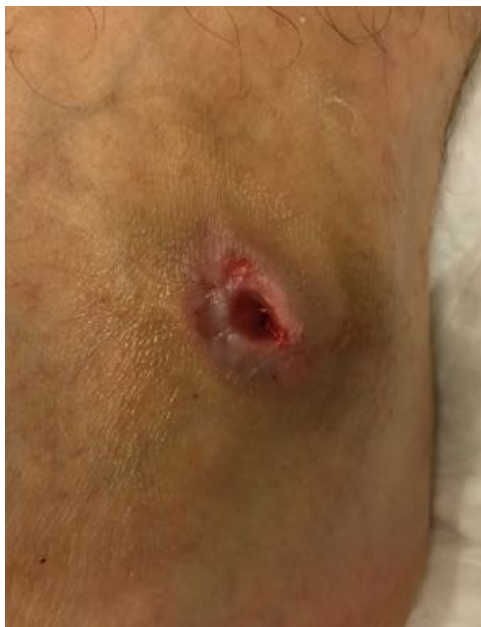Closed in 6 weeks / 18 sessions / no complications

Analysis



08.06.2018

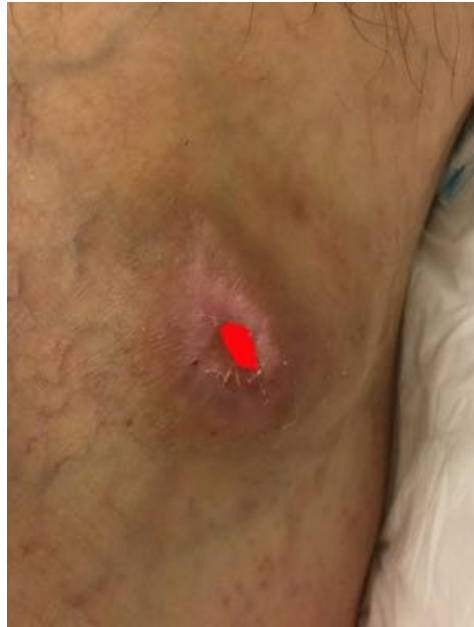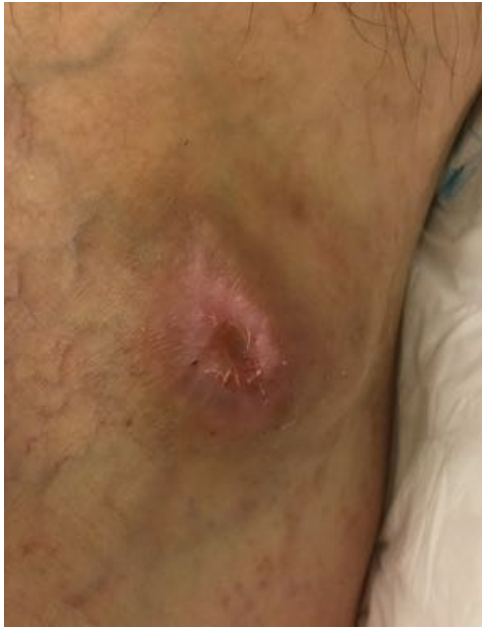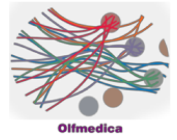
Necrosis:	5%
Fibrin:	61%
Granulation:	34%



25.06.2018

Necrosis:	5%
Fibrin:	0%
Granulation:	95%

Case 13

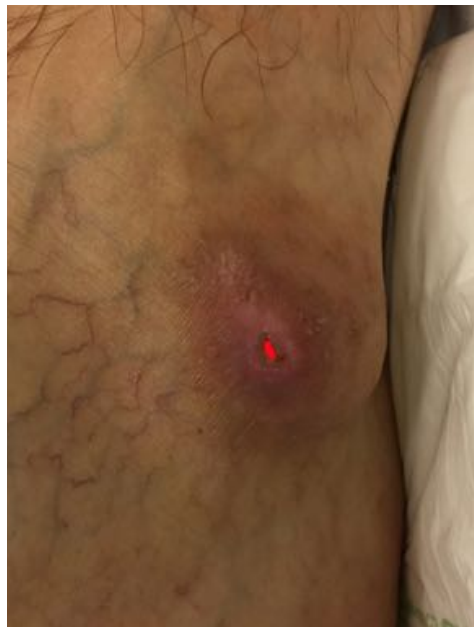
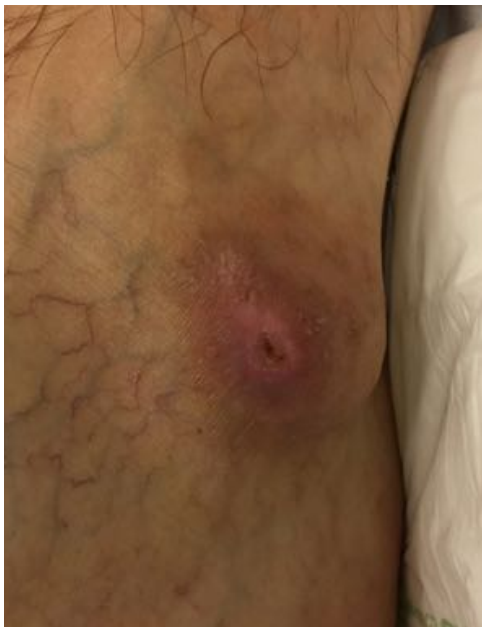
09.07.2018

Necrosis: 0%

Fibrin: 0%

Granulation: 100%



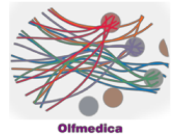
19.07.2018

Necrosis: 0%

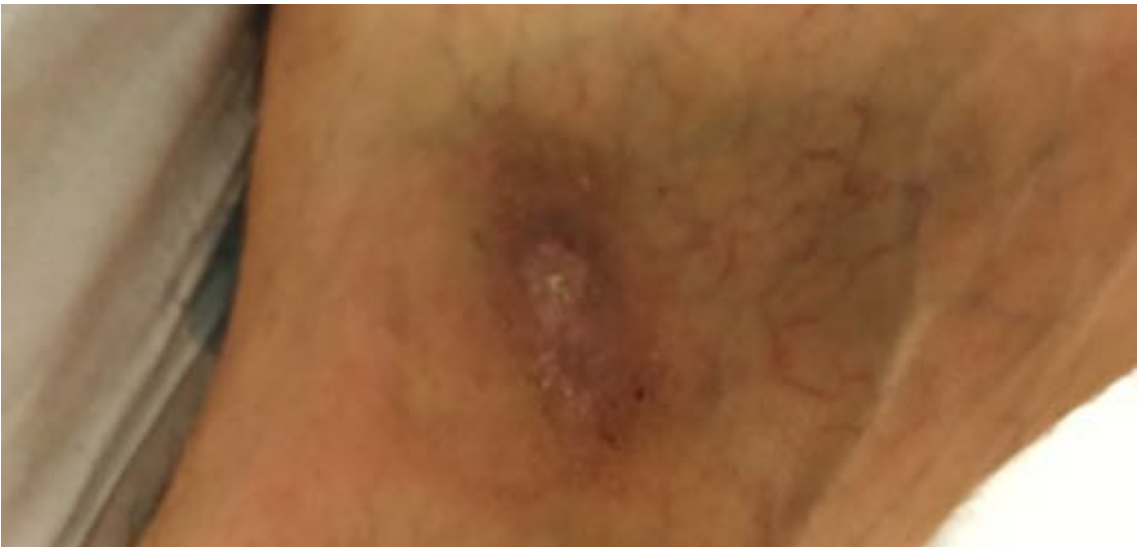Fibrin: 0%

Granulation: 100%

Case 13



Result 24.02.2017



Evolution

