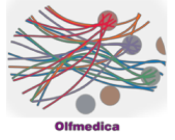


## Case 12



## Case Details

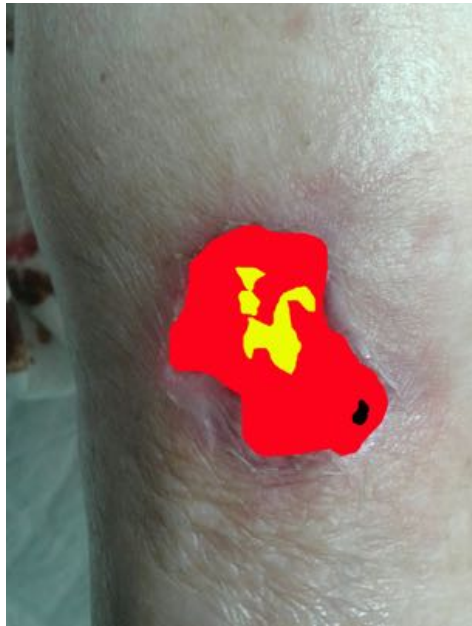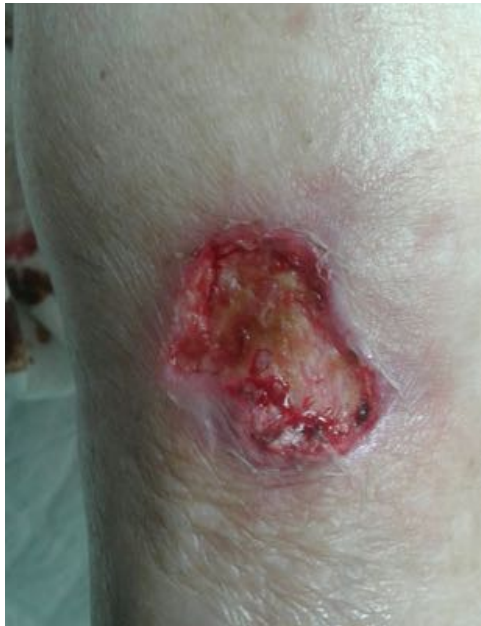Male 85 years

Preconditions: arterial hypertension, stroke and chronic venous insufficiency and treatment with antihypertensive drugs and ASA

Traumatic ulcer at right lower leg developed for 8 weeks

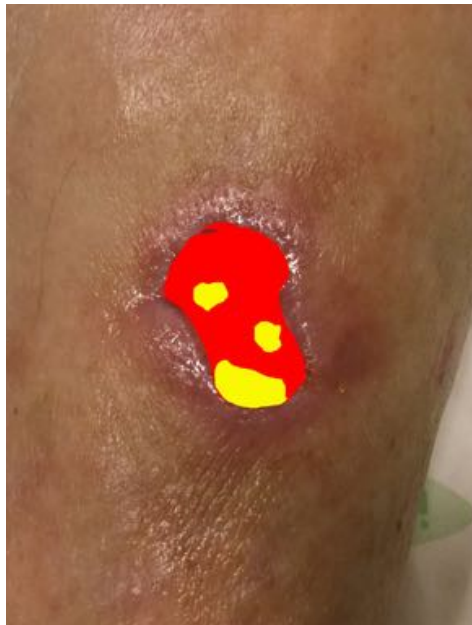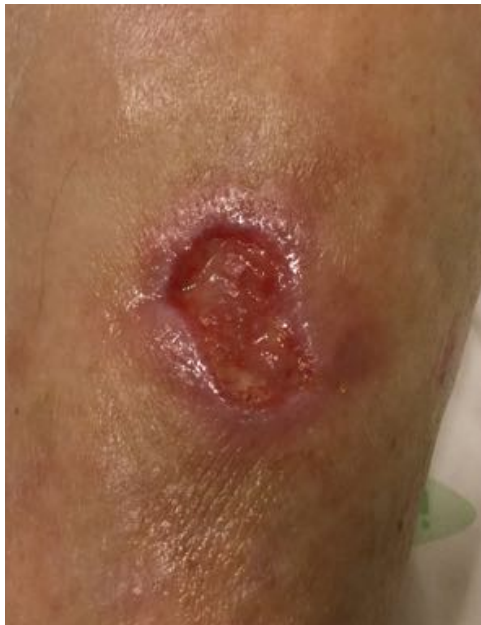3 weeks of treatment / 9 sessions / no complications

## Analysis



11.04.2018

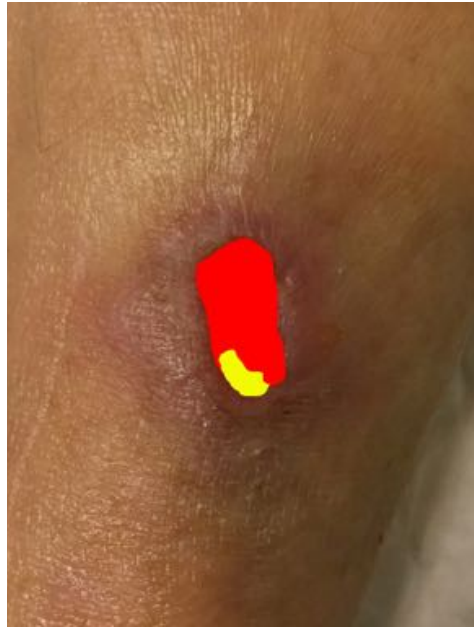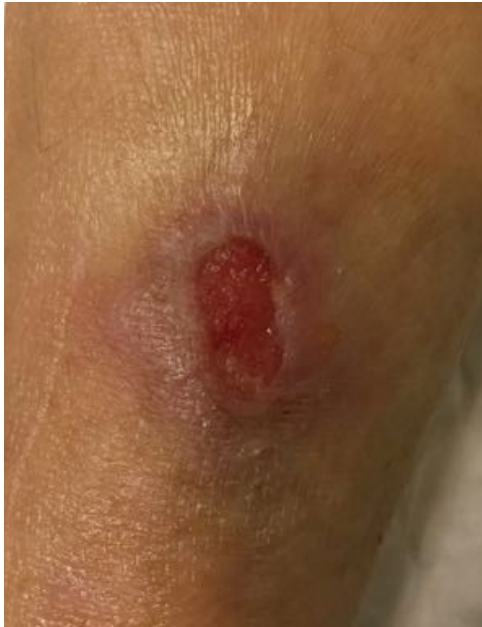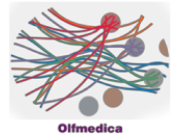
|              |     |
|--------------|-----|
| Necrosis:    | 1%  |
| Fibrin:      | 11% |
| Granulation: | 88% |



13.04.2018

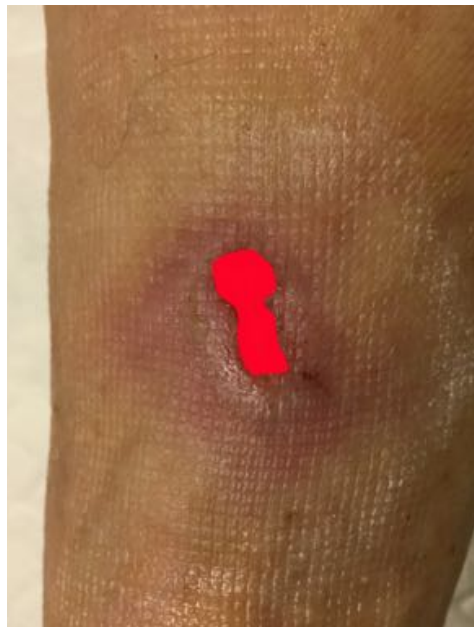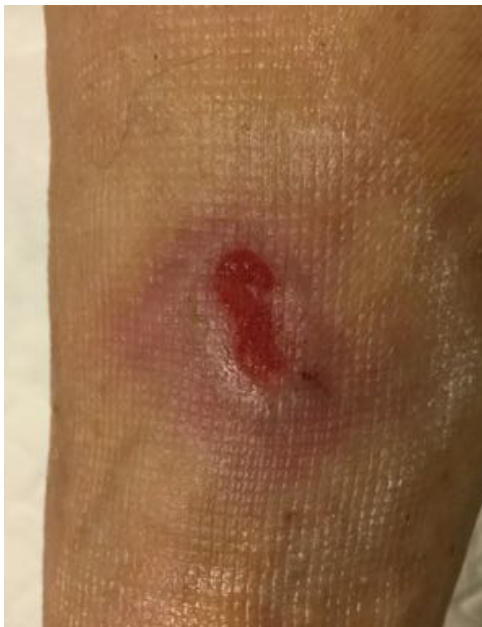|              |     |
|--------------|-----|
| Necrosis:    | 0%  |
| Fibrin:      | 22% |
| Granulation: | 78% |

# Case 12



20.04.2018

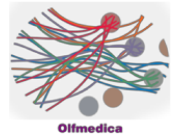
|              |     |
|--------------|-----|
| Necrosis:    | 0%  |
| Fibrin:      | 12% |
| Granulation: | 88% |



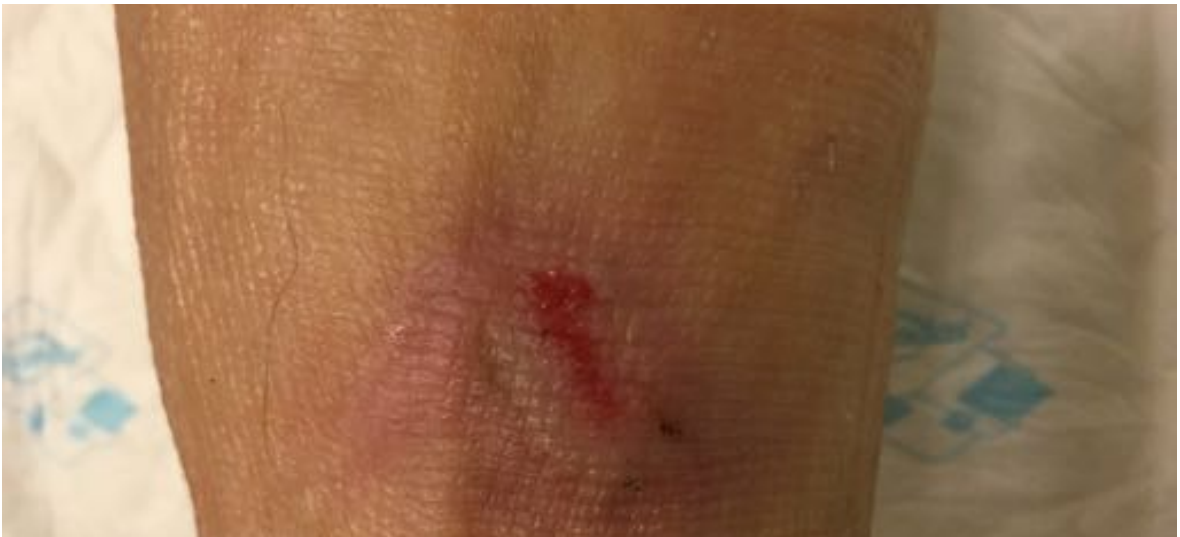25.04.2018

|              |      |
|--------------|------|
| Necrosis:    | 0%   |
| Fibrin:      | 0%   |
| Granulation: | 100% |

# Case 12



Result 24.02.2017



Evolution

