

Case 11

Case Details

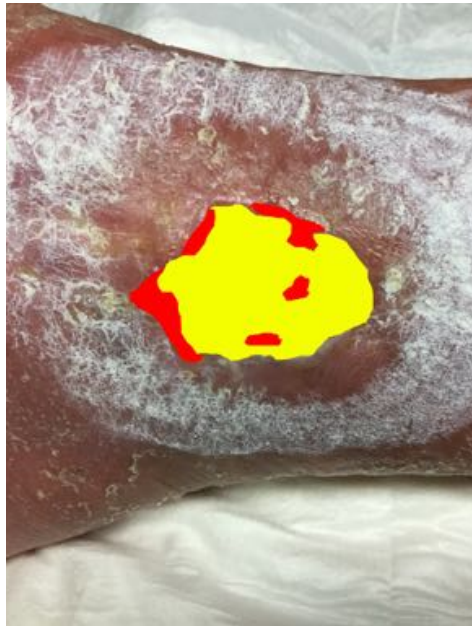
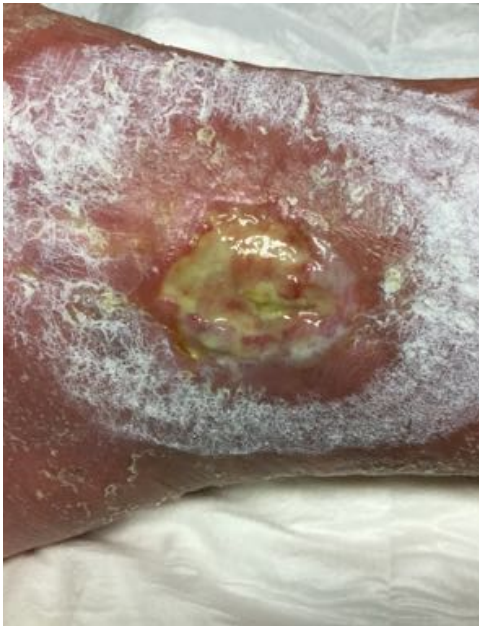
Male 83 years

Preconditions: Arterial hypertension treatment with antihypertensive drugs. Chronic venous insufficiency.

Venous ulcer at exterior left ankle developed for 6 weeks

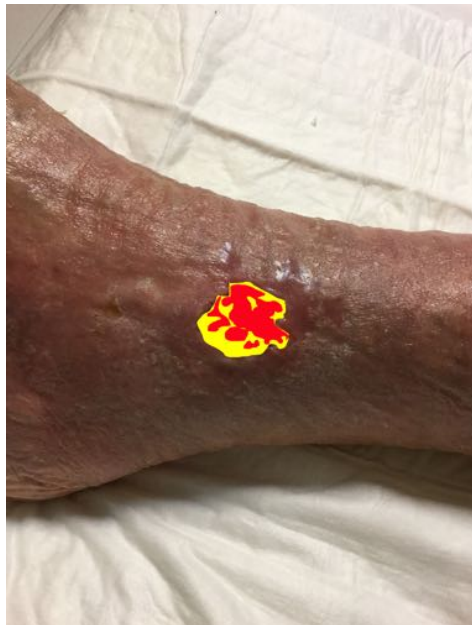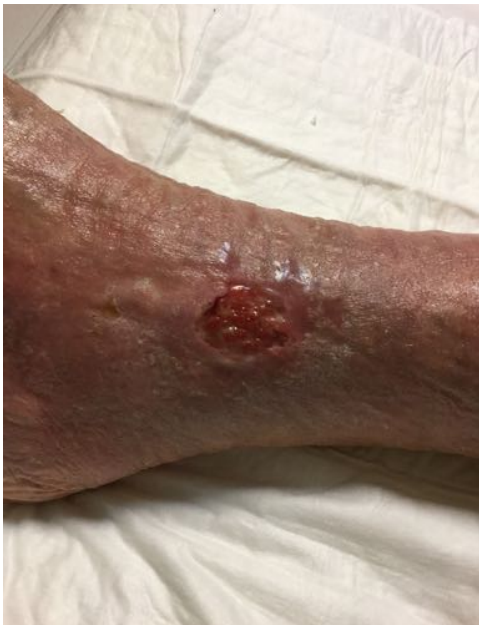Closed within 6 weeks. 18 treatment sessions. No complications

Analysis



18.07.2018

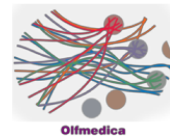
Necrosis:	0%
Fibrin:	82%
Granulation:	18%



05.08.2018

Necrosis:	0%
Fibrin:	42%
Granulation:	58%

Case 11

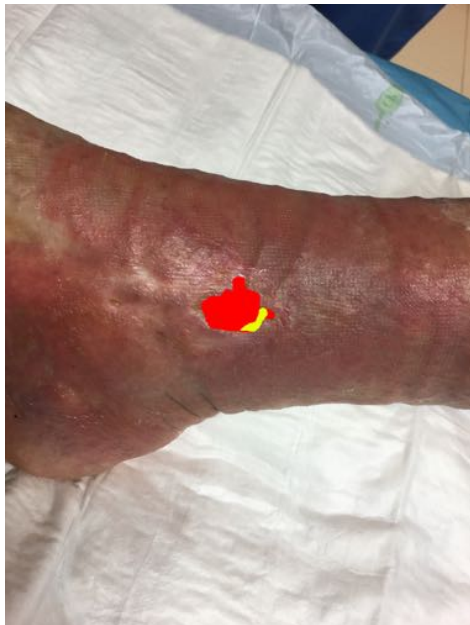
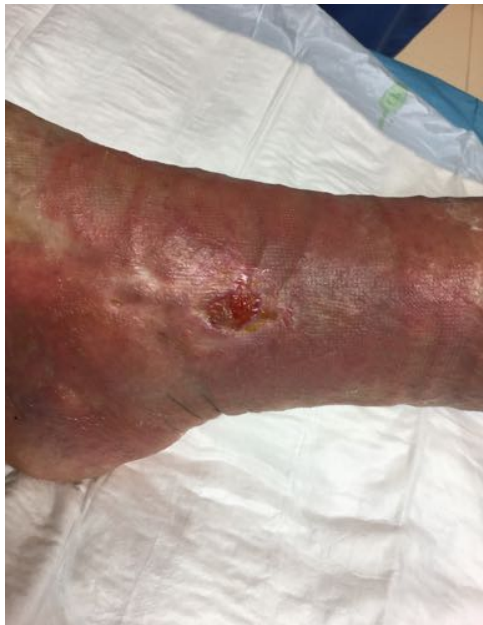
19.08.2018

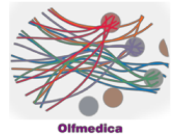
Necrosis: 0%

Fibrin: 10%

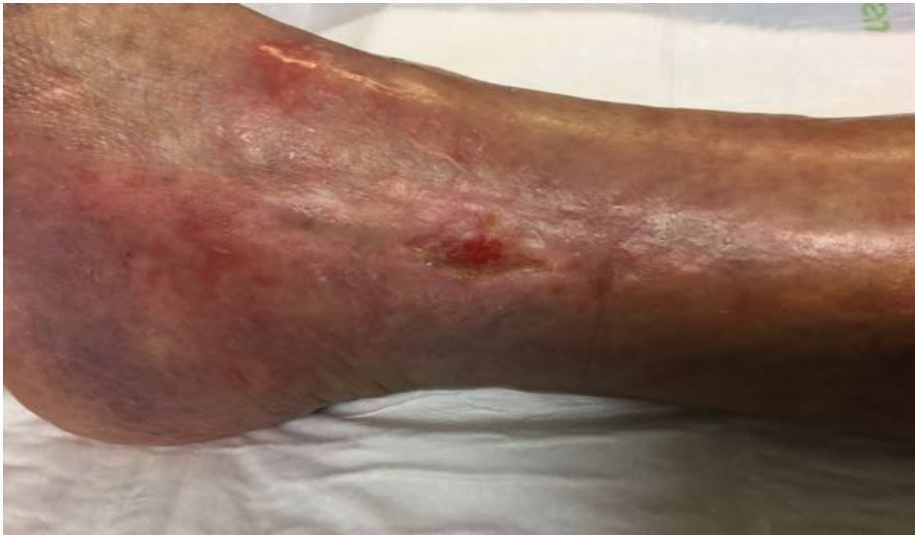Granulation: 90%



Case 11



Result 24.02.2017



Evolution

