

Case 10

Case Details

Female 56 years

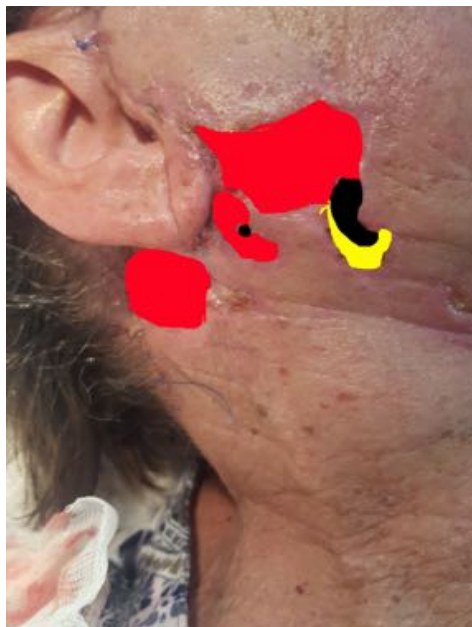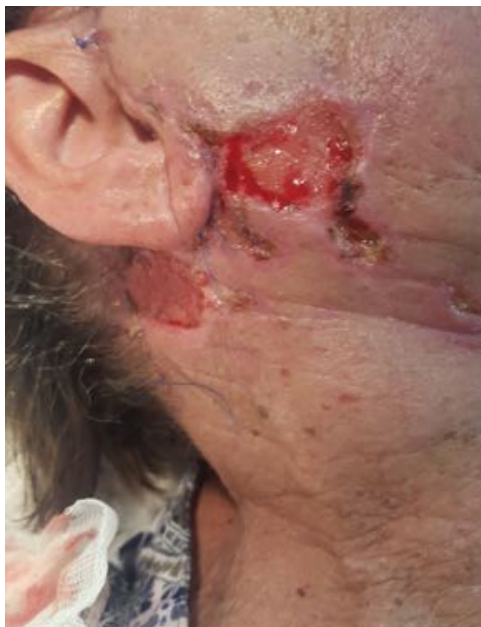Precondition: Arterial Hypertension and treatment with antihypertensive drugs. Smoker.

Necrosis and ulceration of skin following facial lifting procedure.

Facial Ulcer 6 weeks developed

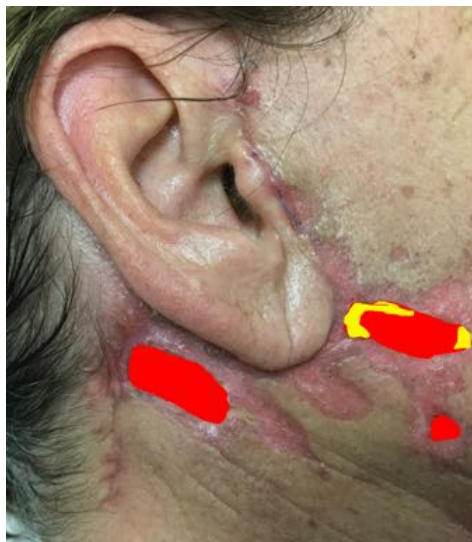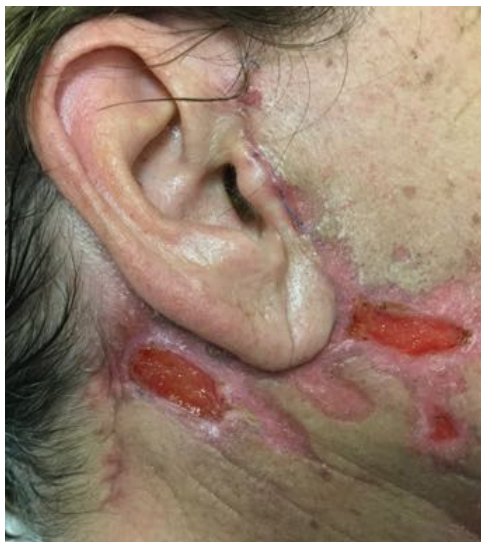2 weeks of treatment / 6 treatment sessions / no complications

Analysis



04.04.2018

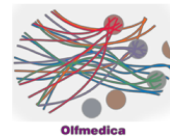
Necrosis:	9%
Fibrin:	6%
Granulation:	85%



13.04.2018

Necrosis:	0%
Fibrin:	12%
Granulation:	88%

Case 10

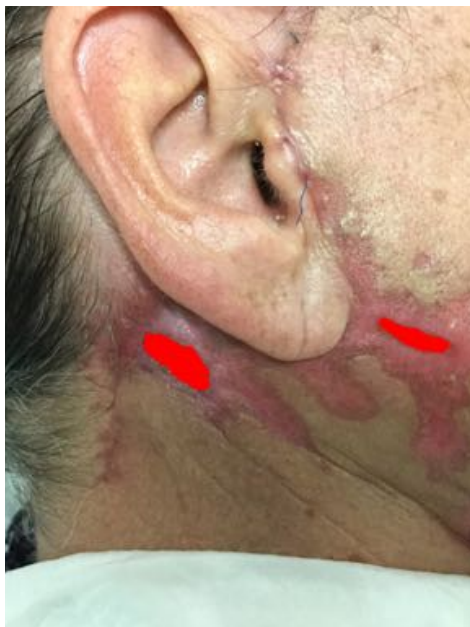
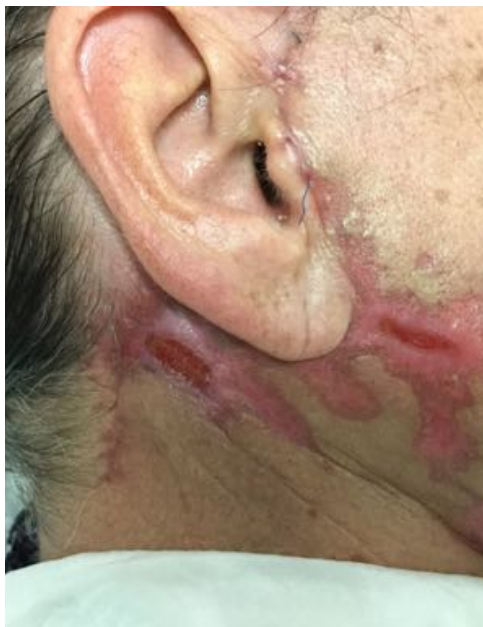
17.04.2018

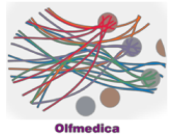
Necrosis: 0%

Fibrin: 0%

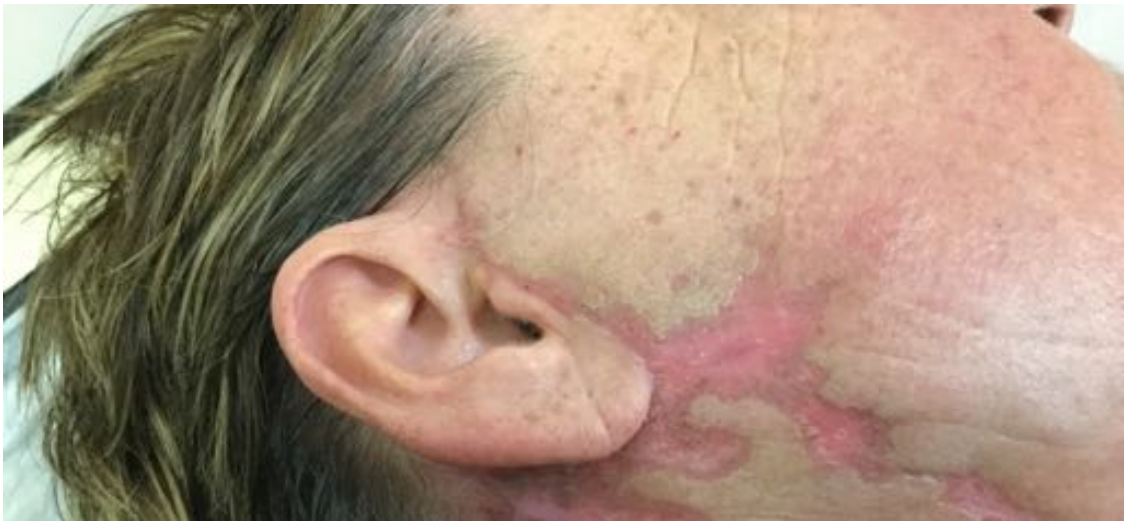Granulation: 100%



Case 10



Result 24.02.2017



Evolution

