

# Case 8



## Case Details

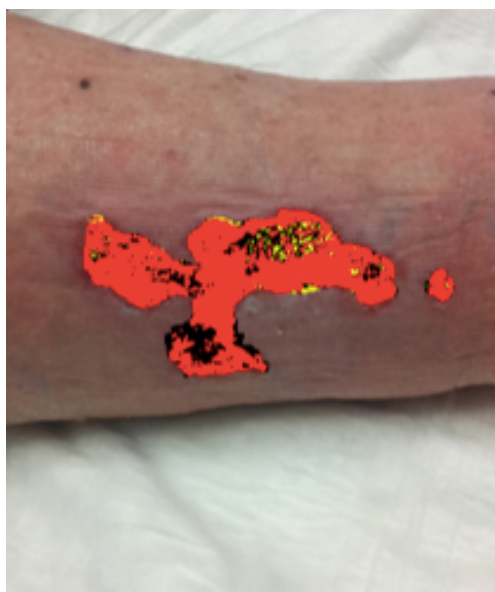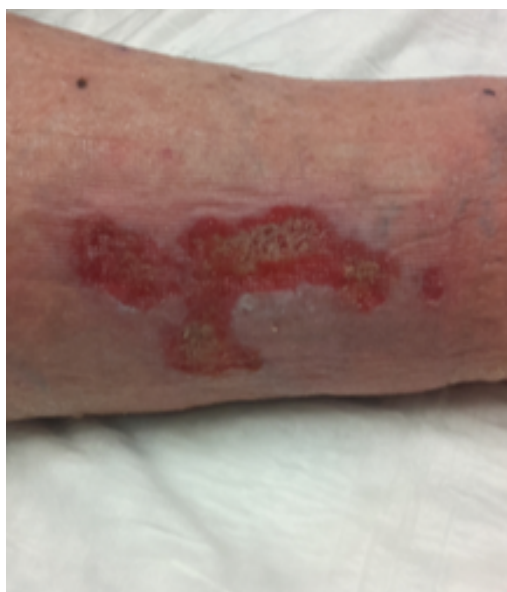Male 70 years.

Background: Cardiopathy, Diabetes mellitus, obesity, CVI. Under treatment with Sintrom, beta-blockers, diuretics and insulin.

Traumatic ulcer of 4 weeks of evolution in lateral aspect of the left leg.

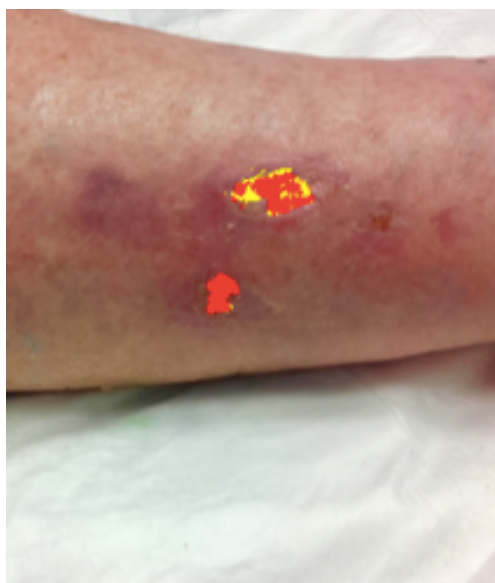
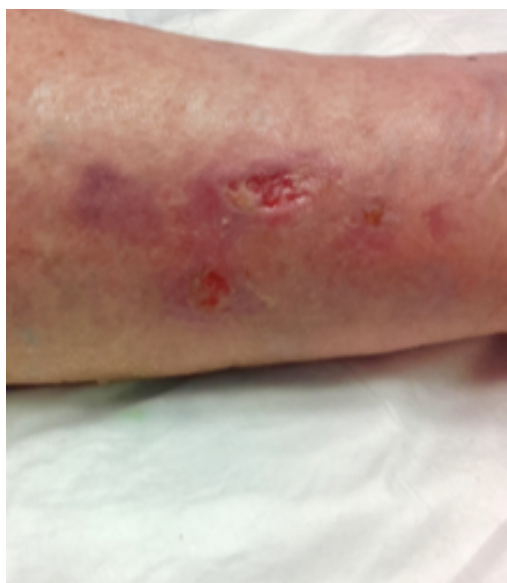Total closure in 2 weeks with 6 sessions.

## Analysis



30.06.2016

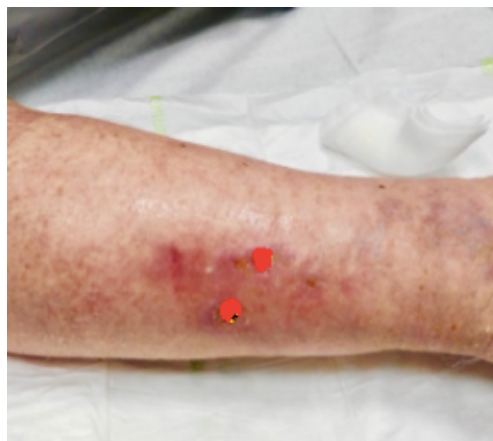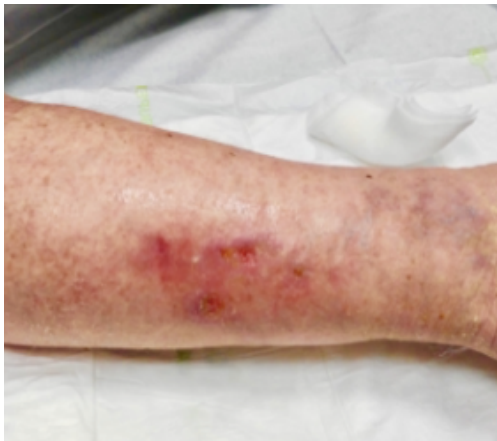Necrosis:	18%
Fibrin:	4%
Granulation:	78%



08.07.2016

Necrosis:	0%
Fibrin:	24%
Granulation:	76%

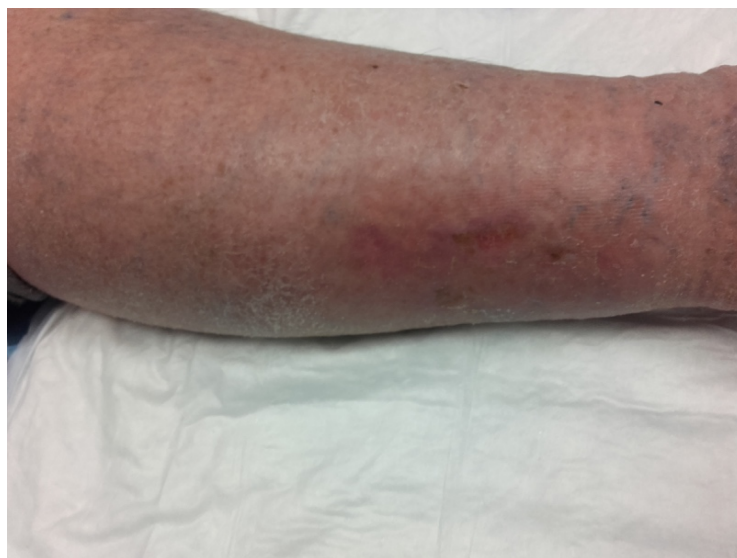# Case 8



11.07.2016

Necrosis:	2%
Fibrin:	2%
Granulation:	96%

Result 15.07.2016



Evolution

